

The Significance of Super Oxidized Solution in Thermal Burns Wound Management

Karthikeyan¹, Ravi Kumar Chittoria^{2,*}, Kanav Gupta³, Jacob Antony Chakiath⁴, Padmalakshmi Bharathi Mohan⁵

¹Junior Resident, Department of Orthopaedic Surgery, JIPMER, India

²Professor & Registrar (Academic), Head of IT Wing and Telemedicine, Department of Plastic Surgery & Telemedicine, JIPMER, India

³Senior Resident, Department of Plastic Surgery, JIPMER, India

⁵Assistant Professor, Department of Plastic Surgery, JIPMER, India

ABSTRACT

Proper dressing and preparation of thermal burns wounds are vital not just for infection prevention but also for potential surgical intervention. This article discusses our evaluation of the efficacy of Super Oxidized Solution in locally treating thermal burns wounds. In the case report performed on a 70 year old female with thermal burns over the gluteal region, Super Oxidized Solution facilitated wound healing and prepared wounds for definitive coverage by promoting granulation and reducing infection, which are the prerequisites for surgery.

Keywords: Superoxidized Solution, Thermal Burns, Wound Management

INTRODUCTION

Various agents such as Povidone Iodine, EUSOL, Acetic acid, hydrogen peroxide, Silver sulfadiazine, and local antibiotic ointments have traditionally been employed in managing thermal burns [1]. These dressings serve the purpose of preventing infection, reducing bacterial load, and promoting granulation to facilitate wound healing. The utilization of Super Oxidized Solution represents a novel approach to wound management. This solution, characterized by a hypotonic nature with an osmolarity of 13 mOsm/kg, contains components like Hypochlorous acid, Sodium hypochlorite, Chlorine dioxide, Ozone, Hydrogen peroxide, and Sodium chloride. Manufactured through an electrochemical process involving pure water and sodium chloride, Super Oxidized Solution generates reactive oxygen and chlorine species during electrolysis. These released species disrupt the cell membrane's integrity, leading to lipid and protein denaturation in single-celled organisms due to osmolarity imbalances. Unlike single-celled organisms, multicellular organisms are less susceptible to such osmolarity changes [2].

CASE PRESENTATION

In this study, a 70 year old female with 15% thermal burns over bilateral gluteal region (Figure 1,4) was enrolled and managed at the Department of Plastic Surgery, JIPMER, Puducherry, India in March 2024 for a

Vol No: 09, Issue: 05

Received Date: May 09, 2024

Published Date: June 11, 2024

*Corresponding Author

Ravi Kumar Chittoria

MCh, DNB, MNAMS, FRCS (Edin), FRCS(Glasgow), FAMS, FTSI, FRSM, FACS, DSc, PhD, MBA, Senior Professor and Associate Dean (Academic), Head of IT Wing and Telemedicine, Department of Plastic Surgery and Telemedicine, JIPMER, India, Phone: +91 94422 85670,

Email: drchittoria@yahoo.com

Citation: Karthikeyan, et al. (2024). The Significance of Super Oxidized Solution in Thermal Burns Wound Management. Mathews J Case Rep. 9(5):166.

Copyright: Karthikeyan, et al. © (2024). This is an open-access article distributed under the terms of the Creative Commons Attribution License, which permits unrestricted use, distribution, and reproduction in any medium, provided the original author and source are credited.

duration of 1month. The study was ethical approved by the institutional review board.

She underwent thorough clinical examination, and essential investigations such as Hemoglobin, Total Count, Differential Count, Bleeding Time, Clotting Time, Erythrocyte Sedimentation Rate, Random and/or Fasting Blood Sugar, Serum Creatinine, Blood Urea, HIV, HBsAg, and Complete Urine Examination were conducted to assess anesthesia fitness and rule out underlying systemic conditions. Additionally, wound swabs were cultured to identify the type of organism and its antibiotic sensitivity.

The wounds received daily once irrigation with Super

Oxidized Solution (Figure 2) and were dressed with gauze soaked in the same solution. Blood sugar levels were regulated using insulin and/or oral hypoglycemic drugs, with input from an endocrinologist in all cases.

The wounds responded to treatment with Super Oxidized Solution, and exhibited healthy granulation following local treatment with Super Oxidized Solution. As the wound bed condition improved, it facilitated performing skin grafting (Figure 3). The study documented the status of bacterial growth, time required for wound sterility, granulation appearance, healing duration, and any associated complications.

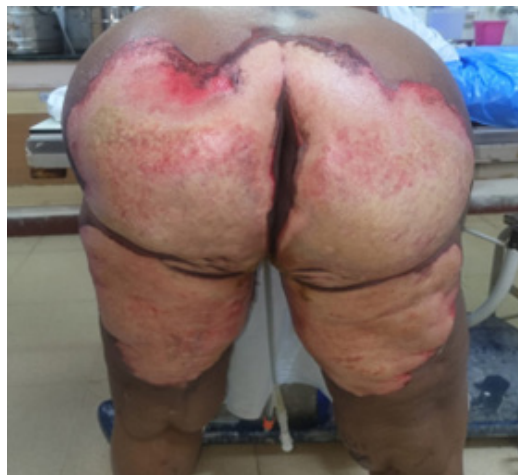

Figure 1. Showing thermal burns over the gluteal region at time of presentation BJWAT Score 48

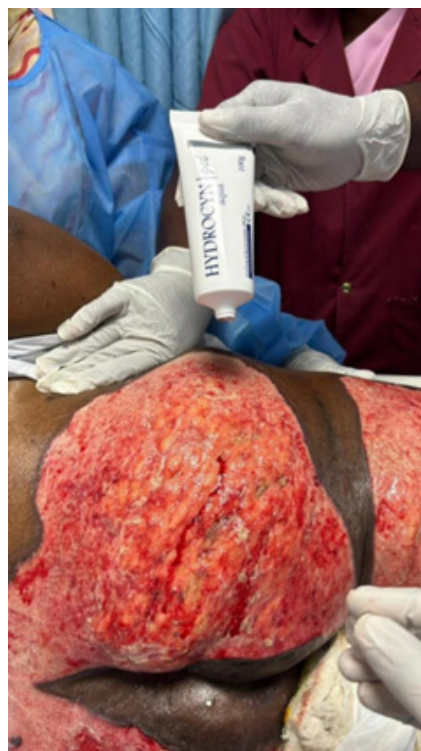

Figure 2. Showing application of super oxidized solution over thermal burns over the gluteal region

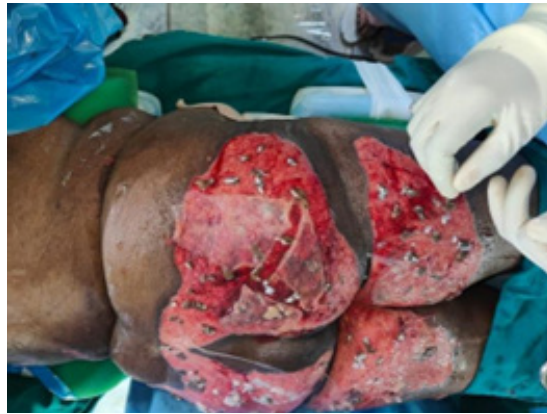

Figure 3. Showing full thickness skin stamp graft with dermal matrix scaffolding with amniotic membrane application. (The wound bed preparation was enhanced by the routine use of superoxidized solution)

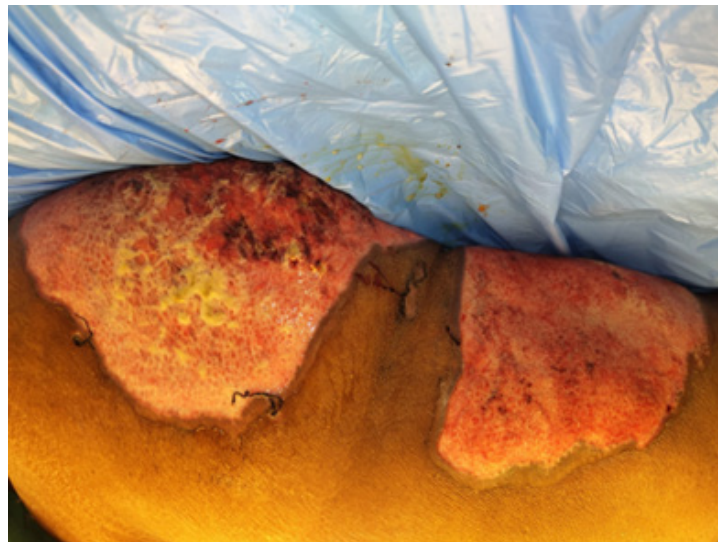


Figure 4. Figure showing condition of the wound at time of presentation (BJWAT wound score - 48)

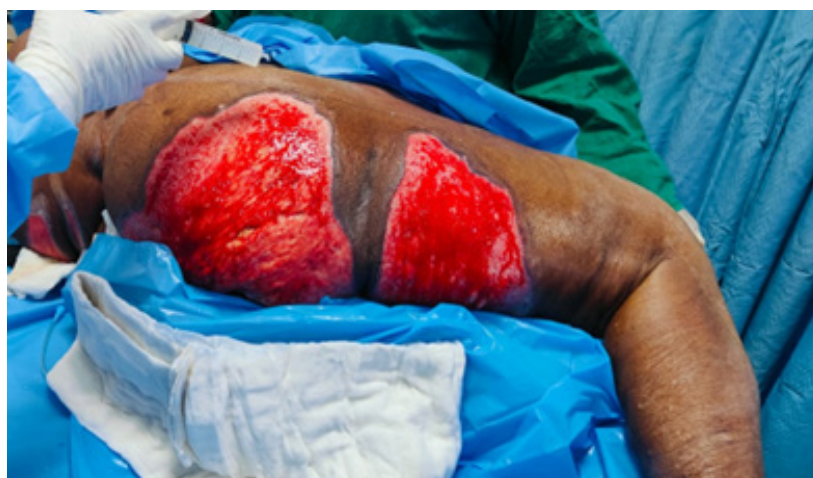

Figure 5. Figure showing condition of the wound after utilization of super oxidized regenerative therapy (BJWAT wound score - 32)

RESULTS

Wound healing was found to be hastened by application of super oxidized solution, proving the efficacy of using superoxidized solution in treatment for wound healing. The condition of the wounds improved following utilization of super oxidised solution regularly. The wound score improved from 48 to 32 (Figure 4 & Figure 5).

DISCUSSION

The prevalence of thermal burns is quite high, such as accidental, self-inflicted, etc., Managing thermal burns and its complications requires a multidisciplinary approach, as it affects various organs and systems in the body. Thermal burns wounds pose a significant challenge to clinicians in their everyday practice and have historically been treated with various local dressings and agents [3].

Super Oxidized Solution represents a newer approach to wound management. It has been investigated by researchers worldwide as a disinfectant for instruments and has been used on humans for various indications, including ulcers, mediastinal irrigation, peritoneal lavage, and hand washing [4,5]. Approved by the European CE KEMA as a Medical Device Class IIb in 2004 and by the FDA in 2005, this solution has garnered positive results in wound management across various etiologies, with no reported reactions or complications in the literature [6].

In our study, we focused on thermal burns wounds and utilized Super Oxidized Solution for cleansing and sterilization. Following 5 days of Super Oxidized Solution application, the wound achieved sterility followed by which full thickness skin grafting surgery was performed. This definitive procedure was undertaken once the wounds exhibited sterile conditions and healthy granulation following Super Oxidized Solution application.

Consistent with previous literature, our study found no noticeable complications associated with the use of Super Oxidized Solution [7-11]. This solution aids in debriding necrotic tissue, reducing microbial load, promoting granulation, and accelerating healing time without causing harm to normal tissue. For patients with small superficial ulcers or those unsuitable for definitive surgery, conservative management with Super Oxidized Solution alone may be sufficient. The moisturizing effect and minimal toxicity of Super Oxidized Solution make it a favorable option for managing thermal burns ulcers. However, further controlled trials are needed to fully elucidate its antimicrobial, anti-inflammatory, and wound-healing effects.

CONCLUSION

Super oxidized solution proves beneficial in promoting wound healing in across a spectrum of cases, regardless of whether they are acute or chronic and irrespective of their underlying causes. Its utility extends to burn injuries as well as within the realm of cosmetic surgery. Our case report findings affirm that super-oxidized solution contributes to enhanced wound healing across diverse wound types.

REFERENCES

1. Tanaka N, Tanaka N, Fujisawa T, Daimon T, Fujiwara K, Yamamoto M, Abe T. (2000). The use of electrolyzed solutions for the cleaning and disinfecting of dialyzers. *Artif Organs*. 24(12):921-928.
2. Nelson D. (2000). Newer technologies for endoscope disinfection: electrolyzed acid water and disposable-component endoscope systems. *Gastrointest Endosc Clin N Am*. 10(2):319-328.
3. Park H, Hung YC, Kim C. (2002). Effectiveness of electrolyzed water as a sanitizer for treating different surfaces. *J Food Prot*. 65(8):1276-1280.
4. Inoue Y, Endo S, Kondo K, Ito H, Omori H, Saito K. (1997). Trial of electrolyzed strong acid aqueous solution lavage in the treatment of peritonitis and intraperitoneal abscess. *Artif Organs*. 21(1):28-31.
5. Sakashita M, Iwasawa A, Nakamura Y. (2002). [Antimicrobial effects and efficacy on habitually hand-washing of strong acidic electrolyzed water--a comparative study of alcoholic antiseptics and soap and tap water]. *Kansenshogaku Zasshi*. 76(5):373-377.
6. Meschter C. (2005). Safety and Efficacy of Treatment for Cutaneous wound study. Comparative Biosciences, Inc. Study Number. pp. 8212-04.
7. Yahagi N, Kono M, Kitahara M, Ohmura A, Sumita O, Hashimoto T, et al. (2000). Effect of electrolyzed water on wound healing. *Artif Organs*. 24(12):984-987.
8. Landa-Solis C, González-Espinosa D, Guzmán-Soriano B, Snyder M, Reyes-Terán G, Torres K, et al. (2005). Microcyn: a novel super-oxidized water with neutral pH and disinfectant activity. *J Hosp Infect*. 61(4):291-299.
9. Sekiya S, Ohmori K, Harii K. (1997). Treatment of infectious skin defects or ulcers with electrolyzed strong acid aqueous solution. *Artif Organs*. 21(1):32-38.

10. Piaggese A, Goretti C, Mazzurco S, Tascini C, Leonildi A, Rizzo L, et al. (2010). A randomized controlled trial to examine the efficacy and safety of a new super-oxidized solution for the management of wide postsurgical lesions of the diabetic foot. *Int J Low Extrem Wounds*. 9(1):10-15.
11. Dang CN, Prasad YD, Boulton AJ, Jude EB. (2003). Methicillin-resistant *Staphylococcus aureus* in the diabetic foot clinic: a worsening problem. *Diabet Med*. 20(2):159-161.