

Cats Have Nine Lives: Resilience of A Country Feline

Alicia Garcia-Falgueras^{1,*}, Francisco Lira Naranjo²

¹Ayuntamiento de Madrid, Madrid, Spain

²Clinica Veterinaria Ávila Fornell, Chiclana, Cádiz, Spain

ABSTRACT

CASE SUMMARY: In a country cat colony of 7 to 14 samples, it was found a young female specimen with a frontal erosion facial wound which affected her semblance. It was noticeable her fragility and inability to hunt or distinguish odors in food. Moreover she presented: a) a good body physical condition (heart and mouth-breathing in normal pulse), b) capacity to move, climb, jump and walk nimbly, c) sight and reflex reactions perfectly preserved, d) intact and voracious appetite and e) completely lack of behavioral disorders or aggressivity. **RELEVANCE AND NOVEL INFORMATION:** The suggested diagnosis of neoplasia, probably squamous carcinoma, was possible to be assigned a posteriori. During the process of assisting her we perceived the effect of face mutilation on her behavior with possible phantom syndromes, the apparent absence or tolerance for chronic pain, the reactions of other cats in the colony living together with a sick mate-partner and her recognition. Suggested method of treatment was the following: daily attention, cat food, medicines and humanitarian euthanasia till Adams stage IV. Colony cats are able to help domestic cats and provide new insights and perspectives into the pets veterinarian treatments which would try to maximize efficiency (OST 218 days) and minimize costs for the general cats welfare. Moreover the study of colony cat brains and understanding their beauty have enormously contributed to the advances in Neurosciences (i. e. Cajal, Hubel and Wiesel). In this case we discuss the phantom mouth/whisker syndromes and the high tolerance of chronic pain in cats. In this case we discuss the phantom mouth/whisker syndromes and the high tolerance of chronic pain in cats.

Keywords: Country Cat, Country Colony, Resilience, Phantom Face Syndrome, Phantom Whisker Syndrome, Squamous Carcinoma.

INTRODUCTION

In the South of Spain we found a colony of country sylvester cats of about 14 specimens (Figure 1). In this set of cats and through about 5 years of

Vol No: 09, Issue: 04

Received Date: March 03, 2025

Published Date: April 14, 2025

***Corresponding Author**

Alicia Garcia-Falgueras

Ayuntamiento de Madrid, Madrid, Spain,
E-mail: algarfal@gmail.com

Citation: Garcia-Falgueras A, Lira F. (2025). Cats Have Nine Lives: Resilience of A Country Feline. Mathews J Vet Sci. 9(4):74.

Copyright: Garcia-Falgueras A, Lira F. © (2025). This is an open-access article distributed under the terms of the Creative Commons Attribution License, which permits unrestricted use, distribution, and reproduction in any medium, provided the original author and source are credited.

work as caregiver, we have found several and varied diseases, some of them treatable with current veterinary techniques, tools or medicines, although others were not. Consequently

multiple casualties have occurred over time. The most common diseases detected are displayed in Table 1.

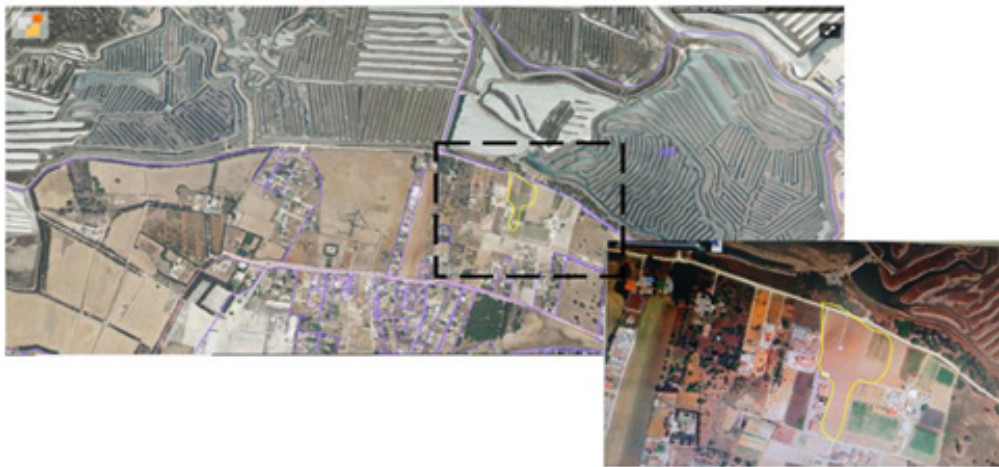


Figure 1. Picture showing an aerial perspective of the place where the colony is located. Although the animals are free to move all around the domain, the area marked on the map is the region where they receive food, care and shelter.

Table 1. In this table is depicted the most common diseases found in the colony. As it is noticeable, most of them already have a veterinary cure and treatment. The reddish square at the end shows the illness we are writing about in this paper

TREATABLE DISEASES AND CONDITIONS DETECTED IN A FELINE COLONY

VISIBLE SYMPTOMS	POSSIBLE CAUSE or DIAGNOSIS	VISIBLE SYMPTOMS	POSSIBLE CAUSE or DIAGNOSIS
Infected wounds	Fights	Skin problems	Parasites, mites, allergies
Eye infections	Conjunctivitis, wounds	Wasting, ulcers, ectropion	Possible leishmaniasis
Extreme thinness	Internal parasites	Limbs fractures	Car or motorbike collisions
Starving thinness	Feline immunodeficiency or feline leukemia	Poisonings	Spoiled or toxic food
Stomach bloating	Gastrointestinal problems, ascites	Dehydration	No access to water
Itching	External parasites	Frontal facial erosion	Possible squamous cell carcinoma, other neoplasms, lymphoma or fungal infections (Cryptococcosis)

In this colony one young female feline appeared with an oral wound. In this case report we are presenting a special rare case of a young female of about 1 year old (estimated by her small size and good teeth appearance), non-pedigree, sylvester or country cat, named "Mouthless", nicknamed "Mouthly" (ML, *SinMorritos-Morris* in Spain), who survived with a basic and efficient treatment an overall survival time

(OST) of 218 days (Figure 2 and 3). In Figure 3 we have drawn on a general x-ray where the affected area in ML was located: all the frontal mucosal mass and part of the bone were affected. The nostril was visible and at a certain point she had a snake-like nose. The affected areas were the frontal sinuses, the nasal cavity and the olfactory mucosa. The advance deterioration of these layers were caused by the

destruction of the zone due to the imposition of emptiness that leads to the carcinoma.

The left eye was lost soon, but the right one was preserved while the treatment was applied. The expressiveness of that unique eye was unbroken, her right eye sight was preserved and she was able to hiss toward her colony mates. As a novelty in the treatment she was cared for and observed in her natural environment and common habitat, where she received daily care and attention. Despite the antibacterial

treatment, carcinoma disease caused a severe declining quality of life (Figures 2 and 3). Consequently, and at the point she allowed to be petted and caught, the humanitarian euthanasia was provided by supplying tranquilizer and phenobarbital, as the better option to be taken for helping her to better navigate her transition. These measurements were supplied according to Spanish laws on the matter (4/2016 and 7/2023) and after an elongation of her life in quality terms of OST = 218 days.



Figure 2. Visual representation of the case reported in this paper, “Mouthless”. It is noticeable how preliminary, when she was found (month 1), the wound was affecting the most external nose and mouth (Adams stage II). Through time and despite the palliative treatment, the carcinoma spreads to almost all her face, affecting one eye and partially the other one (Adams stage IIIb and IV) (month 7).

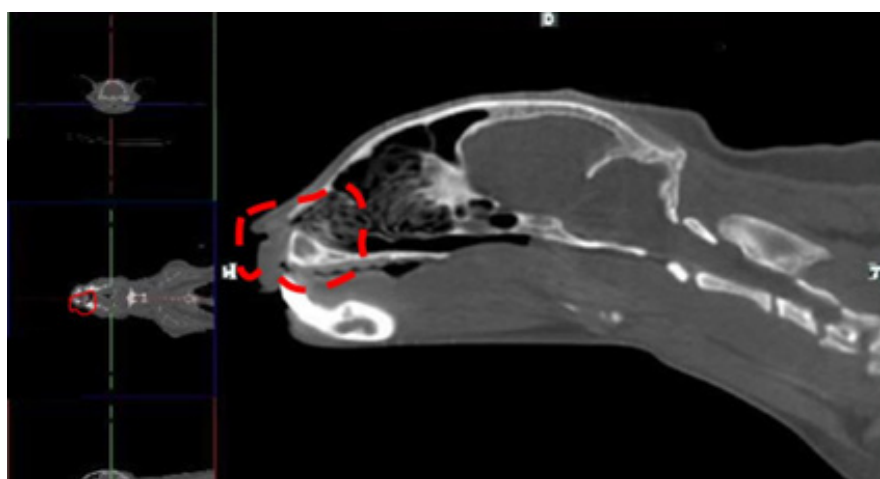


Figure 3. In this picture of a general x-ray of a common cat we have delimited the affected area in ML. As it is noticeable, all the frontal mucosal mass, the nostril, the frontal sinuses, the nasal cavity, the olfactory mucosa and part of the bone were affected. The left eye was lost soon, but the right one was preserved while the treatment was applied.

THEORETICAL APPROACH

The oral cavity, in cats and other species, is vulnerable to be affected by maladies located in the outside environment, because it is the primary interface between the metabolic

digestion and the external world: the most common and prevalent nasal diseases in cats are rhinitis, neoplasia (carcinoma) and polyps [1,2] (Figure 4).

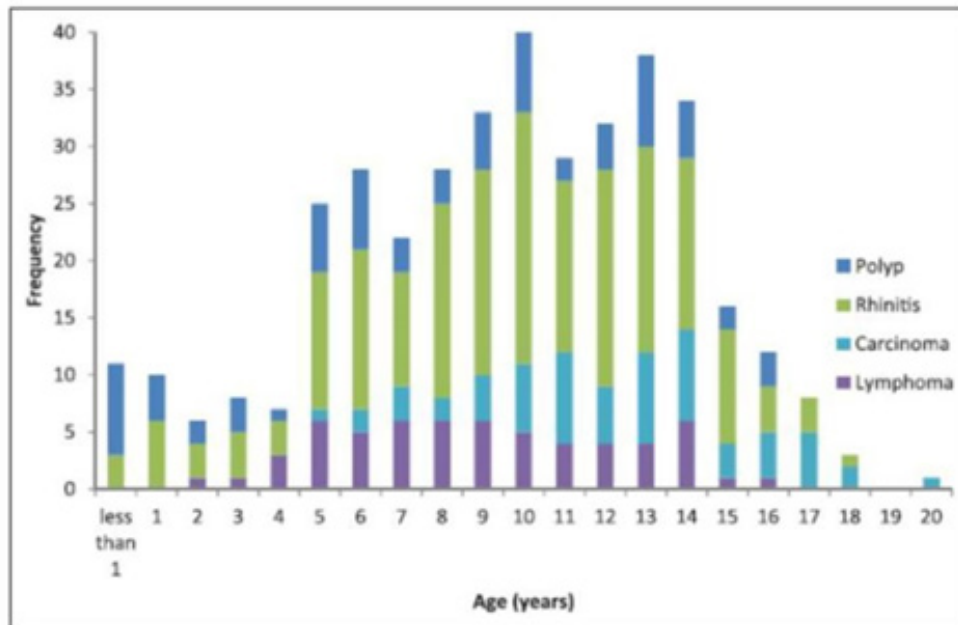


Figure 4. Graph showing the percentage of nasal diseases in cats in different ages through their lives. It is visible how the adenocarcinoma (light blue color) is mostly present in advanced stages of life and in males (age of 5 the first appearance and onwards) (From Ferguson et al., 2020, with permission).

The carcinoma disease occurs more often in cats of pedigree breeds of domestic cats of about 11 years (range 2-20 years) and mainly happens in males (54.3%) vs females (45.7%) cats [1,3-5]. Carcinoma diseases in cats are very aggressive illnesses and they spread out like corrosive acid. The fact that more pedigree cats have been diagnosed with the disease could be probably explained because of the greater likelihood of owners pursuing a diagnosis and treatment although this disease is happening in all the feline kingdom. In the earlier stages, carcinoma facial deformity can mimic lesions caused by infections or miscellaneous agents [2] like Cryptococcosis, for instance, which is caused by a fungal named *Cryptococcus*

neoformans. Crypto happens in cats by inhalation of the yeast form of the organism which might be for instance ubiquitous to dried pigeon or dove feces [2]. However and very often, this Crypto disease is inflammatory, “adding tissue”, and it is restored after veterinarian treatment. Carcinoma, on the contrary, is not adding but subtracting tissues progressively and very quickly and it has very poor prognosis, happening in four consecutive stages, defined by Adams (Table 2). Visually it is noticeable how carcinoma starts affecting the external nose and, in some cases, it even reaches the brain, the frontal cortex [6]. The same multiorgan progressive deterioration might be happening in the internal organs.

Table 2. Different stages of the Adams description in 1998 and revised in 2009. This table includes the modification later introduced, because in stage III sometimes the tumor spreads and reaches the eyeball but sometimes it does not. There are two papers with Adams stages information, one published in 1998 with 4 stages in general. After many observations and cases with the same disease, another paper was published in 2009 which included two substages for the III one, depending on whether the eyeball has been affected or not. Other more subtle internal changes are perceptible with MRI scan, however, the eye affection is detectable without magnetic resonances images

<u>Adams Stage Description (Adams et al., 1998; 2009)</u>	
I.	Confined to one nasal passage, paranasal sinus or frontal sinus, with no bone involvement beyond turbinates.
II.	Any bony involvement (beyond turbinates), but with no evidence of orbit/subcutaneous/ submucosal mass.
III.	Orbit involved, or nasopharyngeal, subcutaneous or submucosal mass. <ol style="list-style-type: none"> a) Tumor extension not in the orbit. b) Orbital involvement.
IV.	Tumour causing lysis of the cribriform plate or extension into nasopharynx.

Several treatments with high costs such as radiation after histopathology tests and radiotherapy with variations in schedule or grades of intensities are possible to apply to cats suffering from carcinomas and prolonging their OST till 365 days. These treatments are having a higher percentage of benefits by slowing down the sequencing of deterioration. They work better when the disease is on less advanced stages of the tumor: stages II and III vs stage IV (152 days) [4,7-9]. However, radiotherapy could also cause severe late-term side effects [7] and histopathological tests might not be required if further highest levels of adjusted treatments to the exact diagnosis are not available. In this paper we offer an alternative and also efficient treatment (OST 218 days) which was successfully applied in an unowned cat which lived in a feline colony, but without excluding the highest efficient protocols of treatment that already exist (histopathological test + radiotherapy, OST 365 days), but that are not always available.

Feline neoplasia and squamous cell carcinoma (SCC) are associated with a poor prognosis and they exhibit a tremendous aggressive biological progression [5] like a corrosive acid. When it is located in an accessible site for a

complete surgical removal the prognosis is better, but that is not very common. The SCC occurs in the epithelial cells of ears, nose, extremities with less hair cover, non pigmented and sun exposed areas of the skin with differentiation to keratinocyte (the pinnae, eyelids, nasal planum, temples and lips). Those areas of the cat body are more vulnerable as a consequence of the harmful ultraviolet (UV) light. The chronic sunlight exposure has been considered the most incriminating factor in the development of this disease in several countries and with different warm climates such as Italy, Mexico or South Africa (for revision see [5]). Moreover other risk factors have been also defined such as rural living environment, the diet with chemical and artificial additives in food (coloring agents, flavor enhancers and conservatives), etc. However, like most carcinoma diseases in the animal kingdom, they are caused by multifactors [10] even by genetic predisposition.

CLINICAL HISTORY AND SYMPTOMS

Several months earlier the female feline (ML) was perfectly ok and was properly orally antiparasitized internally and externally. Suddenly she was shown with a severe frontal

erosion facial wound (Figure 2) and subsequently we carried her to the veterinary location. After a few days of observations and following a preliminary observation, her pathology was described: a) a good body physical condition (heart and mouth-breathing in normal pulse), b) an intact capacity of movement, climb, jump and walk nimbly, c) a sight and reflex reactions perfectly preserved, d) an intact and voracious appetite and e) completely lack of behavioral disorders or aggressivity and e) apparent absence of chronic pain. Because of 1) the locus and progression of the erosion, 2) the described symptoms of the disease, 3) the appearance clear in an Adams stage II and 4) the lack of healing after systemic antibiotic and analgesic treatment, a posteriori possible diagnosis of squamous carcinoma was suggested.

Her observed chronic symptoms were facial deformity (Adams stage II), nasal and ocular discharge, sneezing, and open-mouth breathing. Her brain was not affected nor the laryngeal mass or structures involved in deglutition, digestion or excretion (Figures 2 & 3). Differential diagnosis with a biopsy or histopathological test was not needed because radiotherapy treatment was not available to apply.

Considering she was a rare case of the disease because of her gender and age and implementing humanitarian treatment to the maximum, we decided to provide her attention for her life endurance by applying the available veterinary resources for a palliative treatment. The absence of anhedonia by distinguishing and eating foods, her daily presence to be fed in a free and natural environment, her normal body movements, the absence of typical pain-related

behaviors (no increase vocalization, no decreased appetite, no change in gait, no irritability, no hiding or isolation, no overgrooming) and the impossibility of catching her without a trap cage were her vital constant vindications of her existence and desire to live.

Taking into consideration the toxicity of the radiotherapy, or chemotherapy with an overall survival time (OST) mean of 365 days (range from 123-531 days) [3,4,7], this alternative treatment and perspective would also be applied because it reached an increase for her OST of 218 days (about 8 months). Moreover, during the palliative treatment of the disease we could distinguish some undiagnosed non describe symptoms, such as the phantom syndromes and the high tolerance for chronic pain in cats, to be analyzed for future sick animal patients with the same illness with or without pedigree. This is an alternative therapeutic option which offers a different approach but not excluding the highest efficient protocols of treatment that already exist (histopathological test + radiotherapy), which are not always available.

We used a stethoscope to listen and value her heart beating while she was eating. Despite the fact she could not breathe with her nose, like a brachycephalic dog, her natural rhythms were in balance. We also checked the pH of her urine during a spread diffusion marking episode in the colony using pH test strips and the result was a basic one, around 6. The carcinoma caused her quality of life to decline progressively, as it is explained with Table 3 and Figures 5-7.

Table 3. Scale of 5 points describing how the perception of the external world through all five senses in cats plus the balance sense. They are all very relevant for their quality of life (touch, sight, hearing, smell, taste and balance). The disease starts deleting their nose and whiskers, affecting smell, touch and balance, which are so relevant for a cat to perceive the external world and to adapt their movements and behavior. When their vision is also compromised, four senses of six, the quality of life is drastically reduced. This table is making an emphasis on the adherence to permanence in life under good conditions per species and according to their senses.

SCALE FOR QUALITY OF LIFE

5	<ul style="list-style-type: none"> • Sense of sight, equilibrium and smell preserved. • Whiskers intact.
4	<ul style="list-style-type: none"> • Nose and breathing affected. • Whiskers affected.
3	<ul style="list-style-type: none"> • Nose and mouth eroded. • Whiskers absent.
2	<ul style="list-style-type: none"> • Sense of smell absent. • Partially affected sense of view.
1	<ul style="list-style-type: none"> • Sense of view affected. • Motor coordination, balance and equilibrium compromised.

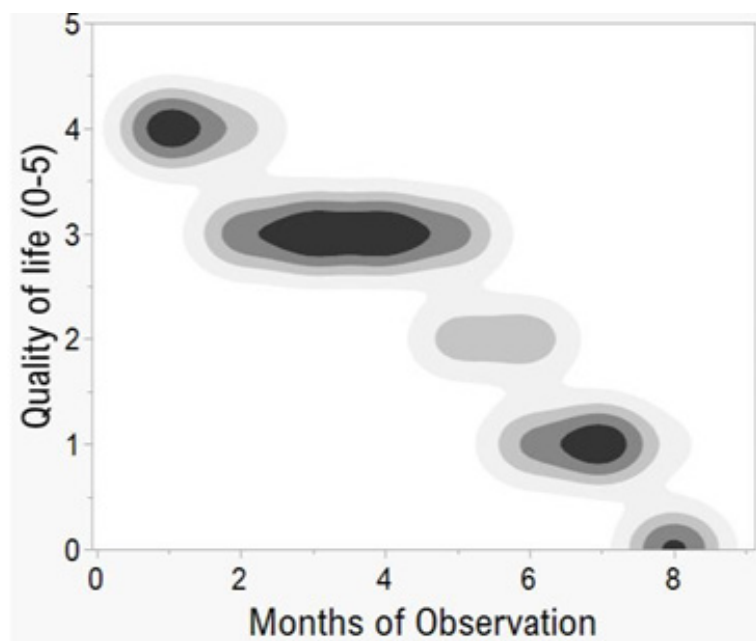


Figure 5. Graph showing how the quality of life, measured by following the description in table 2, was decreasing for ML, through the months of observation and treatment. Here balance, smell and view senses were progressively deteriorating. Senses in cats are all very relevant for their quality of life and they have six: touch, sight, hearing, smell, taste and balance.

When their vision is also compromised (two eyes affected) and four senses of the six they have are compromised because of the carcinoma progression (sight, smell, balance, touch), then the quality of cat's life is drastically reduced and humanitarian euthanasia would be the treatment to apply.

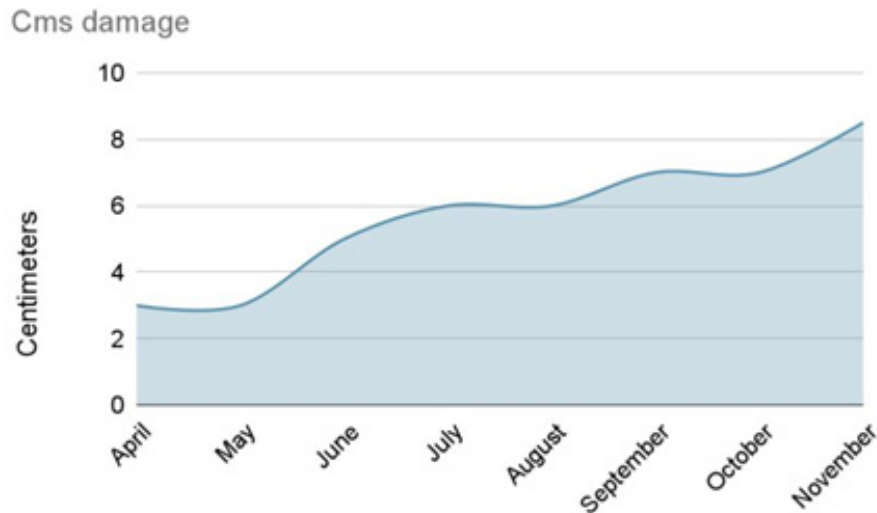


Figure 6. Graph showing the extension of the mouth wound in centimeters. The broadening of the wound in the affected face was estimated from the absent nose to the end of the sore on both sides.

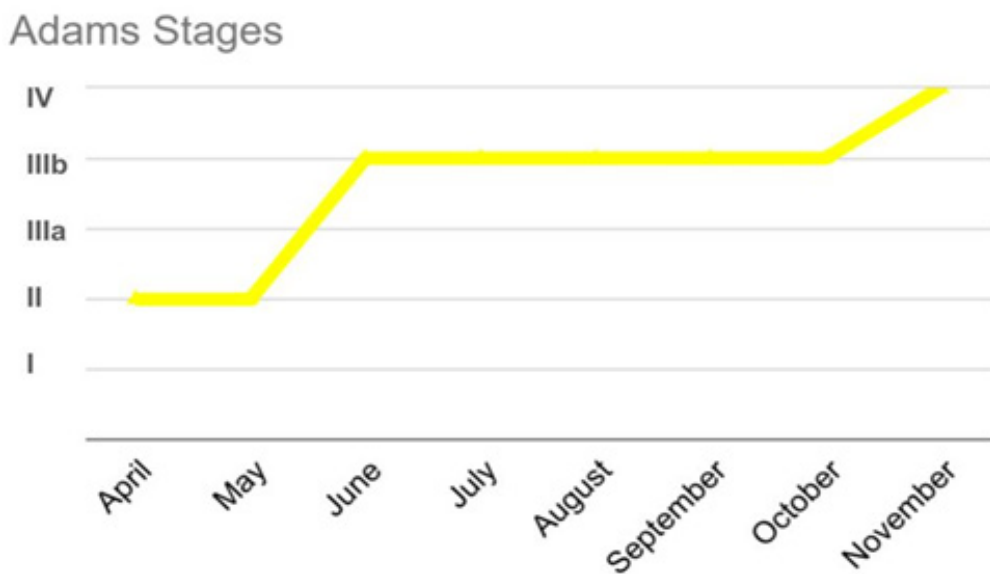


Figure 7. Different Adams Stages where ML went through. It is noticeable how we firstly found her in stage II and very quickly, in a few weeks, she reached stage IIIa, because her left eye was lost. However, the treatment we provided was able to sustain that stage for quite a number of months, giving more life and increasing her OST till 218 days.

While her wound was getting bigger, taking more nasal planum and affecting the right eye and surrounding structures, the Adams stages [8,9] were also higher (Table 3, Figures 5-8). When we first found her she was in stage II but very quickly, in a few weeks, she reached stage IIIa (left eye lost). Her disease took hold onto her mouth and nose,

affecting her breathing and sensory perception with no whisker. The left side of her face was damaged first. However, the basic treatment we provided was able to sustain that stage for quite a number of months, giving more quality of life without infections and increasing her OST till 218 days.

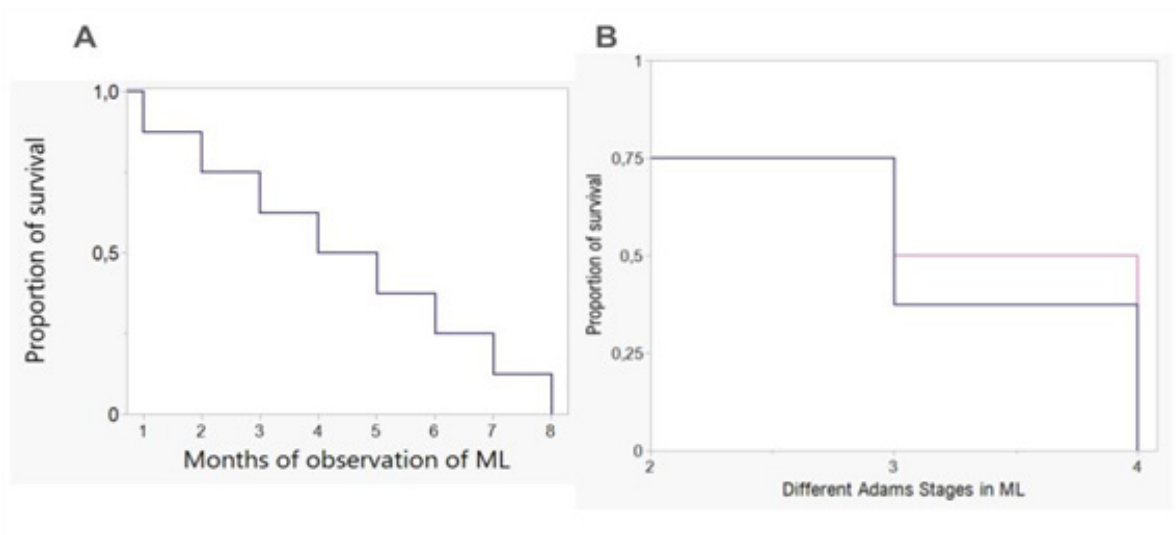


Figure 8. Graph of Kaplan-Meier showing the decreased survival of this disease, as shown by the case of Mouthless. On the left in A figure it is depicted how the survival rate was drastically reduced through progressive months of palliative treatment and observation. On the right, in B figure that decrease is also predicted for the different Adams stages where ML went through. The proportion of survival rate is estimated and informs about the duration times until the occurrence of a specific event (death). It is estimated by this individual case with the provided medical treatment. Without that palliative care, the duration in months would be much shorter. Each point in the graph informs about the status at last observation and the time to event (decease).

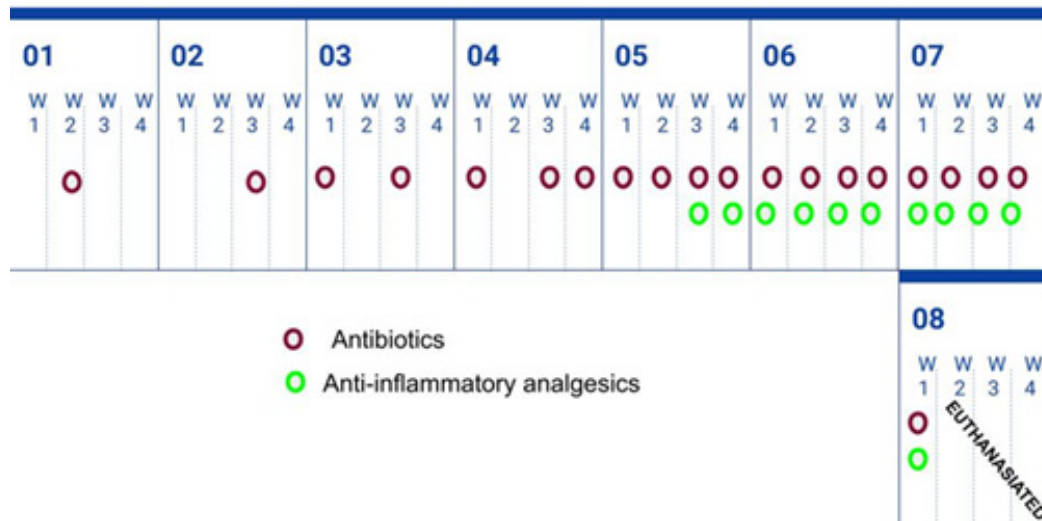
TREATMENT

During the time of palliative treatment we provided her with prescription medicines of antibiotics and analgesics. The control and asepsis of her wound was crucial to avoid lethality and faster spread of the tumor. The colony beds and the food utensils were vigorously cleaned very often or daily with chlorine or bleach diluted in water and soap. ML received her food in a different place and dish than the other cats and with a specific spoon.

As it is noticeable in table 4, antibiotics were supplied in doses of 25 ml/day (fluoroquinolone antibiotic), 5 days/

week and later on we included analgesics 6 ml/day (non steroid COX-2 inhibitor), 3 days/week. At the proper moment for her, the euthanasia was carried out by first administering orally tranquilizers (Acepromazine) and after several hours, intravenous embutramide. It was supplied at the point she wanted and allowed to be caught, not earlier. The humanitarian euthanasia was the better option taken to help her better navigate her transition, according to current Spanish law on the matter (laws 4/2016 and 7/2023) and after an elongation of her life in quality terms of OST 218 days.

Table 4. Schedule showing how the medication was applied. At the beginning it was difficult to find the cat in her natural free environment and the dispensing of medication was delayed. But as soon as she realized there was a source of daily care for her, she appeared quotidian then consistent and systematic treatment was possible to supply. As it is noticeable in table, antibiotics were supplied in doses of 25 ml/day (fluoroquinolone antibiotic), 5 days/week and later on we included analgesics 6 ml/day (non steroid COX-2 inhibitor), 3 days/week. The euthanasia was carried out by first administering orally tranquilizers (Acepromazine) and after several hours, intravenous embutramide. This procedure was in agreement with Spanish laws 4/2016 and 7/2023.



With this treatment we were able to keep under control the infection of the wound, considering where she was living, in a natural environment exposed to dust, dirt, other animals like insects (wasps and snails, which tried to explore her injury). The absence of infected foci was quite a feat also for her with her cleaning daily routine of enormous merit. She spent hours washing the affected area with her saliva by licking his little paws and passing it over the wound. Because of this activity in the last stage of the disease she presented sores on her paw and bruises on her tongue. Her resilience was also palpable when she was able to survive the most heating months of the year during a hard Summer and the torrential rain that happened in Spain in October at the beginning of Winter (cats have nine lives). Her wound was clear and clean with no suppurations till the last of her days (Figure 2).

DISCUSSION

Previous neuroscientific research with cats has been very useful for understanding the human brain (Cajal's

studies about regeneration after injury to the nervous system) or the eyes and sense of sight (Hubel and Wiesel's descriptions about eyes functioning) [11], but also for the human proprioception or kinesthesia and the organization of the human senses for position and movement [12]. However, the chronic pain in cats or the phantom mouth/whiskers syndromes in patients with squamous carcinoma are very little studied topics or completely unexplored fields respectively that would certainly provide interesting information about the mammalian brain functioning.

Phantom syndromes

The loss of certain parts of the body because of a carcinoma, in such a quick and sudden way, may cause that the brain representation of those body areas still remains very active. Animals who are suffering from a neoplasia, carcinoma or squamous carcinoma might still be feeling their whiskers or mouth (Figure 9), like they were intact and as it could happen when a limb is amputated.

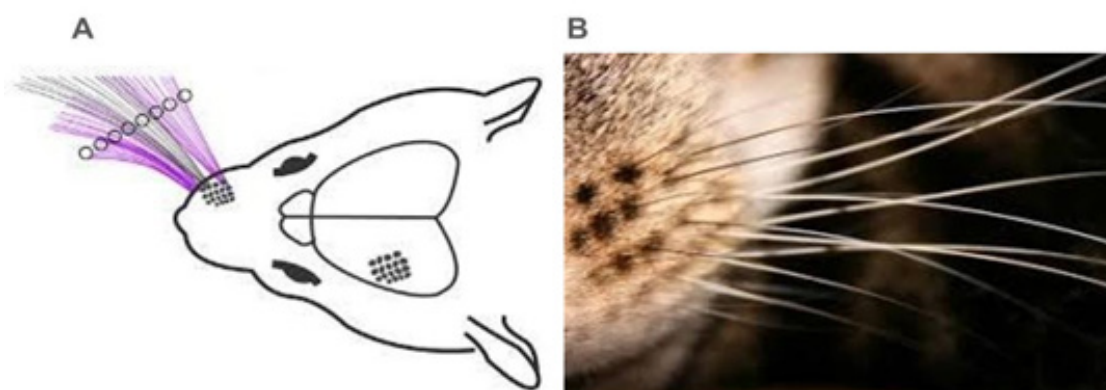


Figure 9. Cats as mice have whiskers which enable them to perceive the external world. In picture A it is visible how in mice each individual whisker is having a specific topographic representation in the ipsilateral hemisphere of the motor cortex. Picture B shows the distance and distribution of the cat's whiskers to perceive. Phantom whiskers syndrome might occur in cat brains because of the loss of certain parts of the body because of a carcinoma, in such a quick and sudden way. The sensitive inputs of mouth and whiskers brain representations might still remain very active and consequently maintain the sensations and provide motor outputs to the body, even without external stimulation.

As a contribution from our scientific behavioral observations, we saw how ML had this phantom syndrome for her whole face and for her whiskers: while she was grooming her face, her front paw completely and clearly traced the original shape of her face. Several times, her paw went from her cheek to the end of her nose, ignoring the absence of nasal mass and exactly the same as any other cat without carcinoma could do in a self grooming episode. During those moments, her brain activation for the feeling of those areas would be stronger than the absence feeling or other sensations, like pain. That is how we really noticed the shape of her face and we saw again the whole semblance and identity of ML. Phantom mouth/whiskers syndrome might occur in cat brains because of the loss of certain parts of the body because of a carcinoma, in such a quick and sudden way. The sensitive inputs of mouth and whiskers brain representations might still remain very active and consequently maintain the sensations and provide motor outputs to the body, even without external stimulation.

We also found, through our scientific observations, that a small straw had been stuck to her wounded face in the side where her only eye was functioning. We tried to take it away but her impressively fast reflexes made it completely

impossible in at least ten of our trials: again and again she guessed the movement and speed of my hand and repeatedly withdrew her face with the straw stick; she really wanted to keep it. At a certain point we understood that straw could be a new part of her face, then it could not be removed. But that was an alien object posed on the wound which could have been a high risk of increased infection. As a hypothesis we would suggest the straw could have been a sort of "prosthesis of her whiskers", to keep that part of her brain active. After a few days it fell off by itself probably because of a head shaking or scratching.

Facial lesion in cats due to carcinoma happens in both sides of the body at the same time, contrary to the limb ipsilateral projection which keeps the connections in the other limb of the other side of the body, then the missing side cannot be compensated with the other one [13,14].

In human beings orofacial phantom pains have been described: the phantom tooth pain was firstly defined in 1978. Exactly the same symptoms were previously also known as atypical odontalgia, idiopathic odontalgia or atypical facial pain [15]. This persistent tooth pain happens following a dental or surgical procedure such as pulp extirpation,

apicoectomy or tooth extraction. Patients feel phantom pain in the absent tooth that cannot be cured by trigeminal rhizotomy or microvascular decompression, because those treatments usually exacerbate the phantom sensations. Ironically the locus of pain in these orofacial sensations does not exist, suggesting that those sensitive feelings are produced by the brain itself. Those empirical facts are pointing out how the uniqueness of ourselves is thoroughly and permanently present in the sensitive nerves of the brain [15]. Moreover, the phantom eye syndrome does occur in human beings and it is defined as any sensation informed by a patient who had anophthalmia with an anophthalmic cavity [16]. It might produce phantom vision, phantom pain or phantom sensations and it is treated with drug therapy and psychological approach. After a limb amputation more than 90% of patients experience phantom phenomena, but people who have lost an eye suffer from phantom eye syndrome in 46-51% of the cases [16].

High tolerance to chronic pain in cats

Contrary to what is experienced by people, the pain for cats has a completely different tolerance threshold. Cats are able to cope with this distressful sensation and adapt to chronic pain till a really unknown extreme for human beings. That is why the study of pain in cats can not have any shadow of anthropomorphism, because that approach would be wrong and mistaken, preventing us from seeing the complete brain processes carried out for cats to successfully cope with pain. The transition process of the illness and analysis of the death were researched and addressed in this paper in an alienated way of its semantic complexity, that is an inevitable inherent feature of the same vital process for human beings.

Cancer in cats is one of the most common causes of chronic pain and involves the affection of sensory external stimuli (located wound in mouth) but also cognitive (phantom syndrome) and affective (contemption reactions). The word chronic implies a long lasting duration and in pain many nociceptive inputs might have a role in its presence, but currently there are no clinical tests or objective measurement which would give relevant information about the perception of pain in cats. However, cancer pain is considered a specific type of pain which involves complex mechanisms including the release of pain-enhancing mediators by the cancer itself originating from the tumor, metastasis or concomitant diseases [17].

However, in this particular case, none or very little behavioral or clinical signs were detected related to the experience of pain (no decrease in activity levels, no changes in appetite, no decrease in socialization, no general loss of interest, etc.).

Living in community

During all her treatment she was coexisting with other cats who live in her colony. At the beginning the other animals were quite hungry and tried to take her food away, but soon they all learned the order of feeding and ML food with the medication was respected. No fights or competition for resources happened, enabling an enduring ML's life as well, because extra wounds from fighting could have been certainly unaffordable to her neoplasia disease. Moreover, the other mates in the colony got the advantages of better quality daily care as well and she indirectly became the feeder of the colony because of her personal fight against cancer.

Recognition

We all knew each day she was alive in that hostile-natural environment was a big goal. Other people who saw her in that public place of where the colony is located would have responded with displeasure because of her distorted semblance. Then she recognized our daily work of caring done without reacting contemptuously. Her appetite remained intact throughout all the days until the last, so medicines were easily provided. No pain-related behaviors (i.e. decrease of appetite or movements activity, changes of postures, hiding, flattered ears, etc) were seen during the treatment. Only she emitted sometimes pitiful vocalizations upon our daily arrival for caring, possibly of welcome or gratitude. At first she ate normal wet food, but at a certain point of her injury, when she was not able to catch food between teeth, we gave her that same food blended and pureed, with some natural protein supplements inside. Thus she could feed herself using her tongue.

As an hypothesis of the cause of the disease it could be suggested the rural environment where ML was found and the constant exposure to the sunlight might have been risk factors to the development of the squamous carcinoma disease. The UV light in the area with sea water in the estuaries might have an increase of reflexion over the skin (Figure 1). However one only case does not make epidemiology. Her late diagnosed disease (likely squamous carcinoma) could be of

help for a better understanding of the risks for health in a rural area.

Her fiercely trying to live and survive were certainly inspirational for this paper because during her transit and while providing palliative care we could learn new concepts. With this palliative treatment it was possible to sustain the IV stage of Adams for a long time (Figure 7) to get a total OST of 218 days with reduced side effects and no suppuration wounds in a challenging natural environment. The costs of this alternative treatment instead of the usual manner treatment (histopathology test + radiotherapy) certainly would deserve consideration for the aim of the feline general healthcares with and without pedigree. Moreover we found the phantom syndromes of face and whiskers and the high tolerance to chronic pain associated with the disease would indeed entitled further attention and research.

CONCLUSION

The case reported of ML was a female cat who lived in a colony and had no owner. In this paper we suggested a method that we applied to ML for a skin carcinoma treatment which reached an OST of 218 days. That method consisted of providing daily pleasant attention, pureed blended cat food, medicines with veterinarian prescription and humanitarian euthanasia till Adams stage IV according to Spanish law. This might be an alternative treatment instead of the highest efficient veterinarian manner of histopathology test and radiotherapy which are not always available. Cats in colonies are able to help domestic cats with or without pedigree and provide new insights and perspectives into the pets veterinarian treatments which would try to maximize efficiency and minimize costs for the general cat's welfare. This suggested treatment with medicines and daily care could be applied equally to domestic cats to enlarge the benefits of decreasing costs in feline care.

Cats in colonies are able to help domestic cats with or without pedigree and provide new insights and perspectives into the pets veterinarian treatments which would try to maximize efficiency and minimize costs for the general welfare of cats.

Caring a feline country colony in field study like this one performed over a public space is certainly a challenge. Despite the constant scrutiny which made the work even more challenging, for the cat too, we were able to prove an alternative treatment which included daily attention without

contempt as an alternative method. This was very opposite to the method that usually has been applied in unfriendly for cats zones, consisting of poisoning water in the cats bowls and causing agonizing and indiscriminate deaths of healthy cats which were non-pest and sometimes also affecting and damaging protected hedgehogs that drink the same water. With this field study an alternative treatment with a consideration toward the lives of animals is proved, aimed to improve the current rules of protection and attention for animals.

This study was defined as a scientific observational design in a field study, with a very respectful perspective toward the life of the animal in her natural environment. With this approach it was possible to see how a cat was able to finely survive with tolerable chronic pain and acceptable sensorial stimulation till Adams stage IV. Moreover we found the phantom syndromes of face and whiskers and the high tolerance to chronic pain associated with the disease would certainly entitled further attention and research.

The fiercely trying to live and survive of the cat studied were certainly inspirational for this paper because during her transit and while providing palliative care we could learn new concepts. With this palliative treatment it was possible to sustain the IIIb stage of Adams for a long time (Figure 8) to get a total OST of 218 days with reduced side effects and no suppuration wounds in a challenging natural environment.

ETHICAL APPROVAL STATEMENT

The work described in this manuscript involved the use of non-experimental (unowned) animals. Established internationally recognized high standards ('best practice') of veterinary clinical care for the individual patient were always followed. Ethical approval from a committee was therefore not specifically required for publication. Although not required, it is stated in the manuscript. This research did not receive any specific grant from funding agencies in the public, commercial, or not-for-profit sectors.

CONFLICT OF INTEREST

The authors hereby undertook their work with complete impartiality and in good faith in what concerns its performance and outcome. They also assure to immediately declare whether any situation that might raise concerns with respect to conflict of interest, impartiality or otherwise affect their position/ability to duly, thus appropriately perform

their professional affiliations without further interest in the subject matter or materials discussed in this manuscript.

AUTHORS CONTRIBUTIONS

AGF conceived and designed the analysis; cared for the animal, collected the data; made graphs data with analysis tools; wrote the paper, discussed the results and contributed to the final manuscript. FLN attended the animal for the exploration, provided the veterinarian advice, medicines and euthanased.

CREDIT OF IMAGES

Graphs and tables presented in this work have been done by the authors or come from files with a free licence in the public domain as Wikimedia Commons. In cases where graphs come with authorship from a published paper, that has been properly quoted and permission from the corresponding author was obtained.

ACKNOWLEDGEMENTS

We are very grateful to the professional staff of the Veterinarian clinic Avila Fornell in Chiclana, Francisco Montiel Colchón, Jaime Bescós Gil and Gloria Chaza Sainz for their attendance during the process of the colony caring. We would like to thank the veterinary team of the feline colony management service in the Madrid City Council, Huanxi YuMa, Pilar Martínez Torreblanca and Marta Medialdea Utande, for their experienced assessment on the matter. I also would also like to thank Prof. Swaab in the Netherlands Institute for Neuroscience in Amsterdam for his encouragement in keeping a finger on the pulse of this project and to the cat Mouthless, (*SinMorritos*), for choosing me to care for her, showing me daily her gratitude and affection and relying on me without doubts.

REFERENCES

1. Ferguson S, Smith KC, Welsh CE, Dobromylskij MJ. (2020). A retrospective study of more than 400 feline nasal biopsy samples in the UK (2006-2013). *J Feline Med Surg.* 22(8):736-743.
2. Pedersen NC. (1992). Inflammatory oral cavity diseases of the cat. *Vet Clin North Am Small Anim Pract.* 22(6):1323-1345.
3. Reczynska AI, LaRue SM, Boss MK, Lee BI, Leary D, Pohlmann K, et al. (2022). Outcome of stereotactic body radiation for treatment of nasal and nasopharyngeal lymphoma in 32 cats. *J Vet Intern Med.* 36(2):733-742.
4. Frezoulis PS, Harper A, Mason SL. (2022). Use of a cyclical hypofractionated radiotherapy regime ('QUAD shot') for the treatment of feline sinonasal carcinomas. *J Feline Med Surg.* 24(12):1212-1218.
5. Laissaoui N, Millán Y, Simon Betz D, El Mrini M, Lamalmi N, Azrib R, et al. (2024). Evaluation of canine and feline tumors in Morocco: Results of a prospective observational study of 250 cases (2020-2023). *Top Companion Anim Med.* 63:100929.
6. Little L, Patel R, Goldschmidt M. (2007). Nasal and nasopharyngeal lymphoma in cats: 50 cases (1989-2005). *Vet Pathol.* 44(6):885-892.
7. Giuliano A, Dobson J. (2020). Clinical response and survival time of cats with carcinoma of the nasal cavity treated with palliative coarse fractionated radiotherapy. *J Feline Med Surg.* 22(10):922-927.
8. Adams WM, Miller PE, Vail DM, Forrest LJ, MacEwen EG. (1998). An accelerated technique for irradiation of malignant canine nasal and paranasal sinus tumors. *Vet Radiol Ultrasound.* 39(5):475-481.
9. Adams WM, Kleiter MM, Thrall DE, Klauer JM, Forrest LJ, La Due TA, et al. (2009). Prognostic significance of tumor histology and computed tomographic staging for radiation treatment response of canine nasal tumors. *Vet Radiol Ultrasound.* 50(3):330-335.
10. Zaccone R, Renzi A, Chalfon C, Lenzi J, Bellei E, Marconato L, et al. (2022). Environmental risk factors for the development of oral squamous cell carcinoma in cats. *J Vet Intern Med.* 36(4):1398-1408.
11. Garcia-Falgueras A. (2024). Symbiotic Relationship Human-Cats: Its Psychological and Physiological Benefits. *Psychol Psychology Res Int J.* 9(1):000398.
12. Proske U, Gandevia SC. (2012). The proprioceptive senses: their roles in signaling body shape, body position and movement, and muscle force. *Physiol Rev.* 92(4):1651-1697.
13. Ramachandran VS, Ary M. (1982). Evidence for a "consolidation" effect during changes in ocular dominance of cortical neurons in kittens. *Behav Neural Biol.* 35(3):211-216.

14. Ramachandran VS. (2005). Plasticity and functional recovery in neurology. *Clin Med (Lond)*. 5(4):368-373.
15. Marbach JJ. (1996). Orofacial phantom pain: theory and phenomenology. *J Am Dent Assoc*. 127(2):221-229.
16. Andreotti AM, Goiato MC, Pellizzer EP, Pesqueira AA, Guiotti AM, Gennari-Filho H, et al. (2014). Phantom eye syndrome: a review of the literature. *ScientificWorldJournal*. 2014:686493.
17. Monteiro BP, Steagall PV. (2019). Chronic pain in cats: Recent advances in clinical assessment. *J Feline Med Surg*. 21(7):601-614.