

Sildenafil Citrate Administration Resulting in Death

Umut Gulacti¹, Ugur Lok¹

¹Department of Emergency Medicine, Adiyaman University Medical Faculty, Adiyaman-Turkey.

Corresponding Author: Umut Gulacti, Department of Emergency Medicine, Adiyaman University Medical Faculty, Adiyaman-Turkey, **Tel:** +90(535) 585 1900; **Email:** umutgulacti@gmail.com

Received Date: 10 Jun 2016

Accepted Date: 20 Sep 2016

Published Date: 23 Sep 2016

Copyright © 2016 Gulacti U

Citation: Gulacti U and Lok U. (2016). Sildenafil Citrate Administration Resulting in Death. *M J E-Med.* 1(3): 016.

ABSTRACT

Sildenafil citrate is a phosphodiesterase (PDE) 5 inhibitor. This paper presents a case resulting in death due to ventricular tachycardia (VT) after taking 100 mg of Sildenafil citrate.

KEYWORDS

Ventricular Tachycardia; Sildenafil Citrate; Cardiovascular Event; Mortality.

INTRODUCTION

Sildenafil citrate is a phosphodiesterase (PDE) 5 inhibitor. Many case reports have described associated with acute coronary syndrome of Sildenafil citrate ingestion [1-4]. However, mortality due to ventricular arrhythmias has not been reported for Sildenafil yet. We described a case of a patient with no cardiac history, resulting in death due to ventricular tachycardia (VT) occurring after ingestion sildenafil citrate.

CASE REPORT

A -56- year old man was brought to the emergency department (ED) with palpitation. After he had taken orally 100 milligram sildenafil citrate tablet (Viagra, Pfizer, New York) because of his erectile dysfunction, the patient experienced palpitation in approximately 6 hours. There were no any cardiopulmonary symptom and disease in the patient's past medical history. A physical examination revealed a body temperature of 36.7°C (axillary), arterial blood pressure of 110/50 mm/Hg, and a pulse rate of 185 beats/min. Sustained monomorphic ventricular tachycardia was determined in 12-lead electrocardiogram (ECG) recorded when the patient was admitted to the ED (Figure 1).

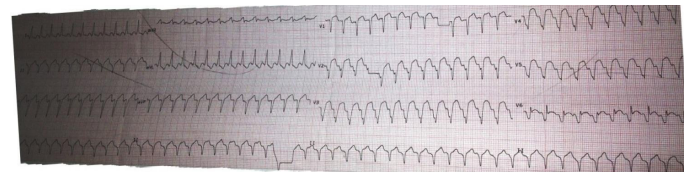


Figure 1: ECG of patient.

Three hundred milligrams of Amiodarone was administered for treatment of VT intravenously. But, VT cannot be returned to sinus rhythm. He was transferred to coronary care unit (CCU) and simultaneously, the patient went into hemodynamic instability there. Electrical cardioversion was performed. Asystole appeared after electrical cardioversion and cardiopulmonary resuscitation was performed. However, asystole did not respond to performed cardiopulmonary resuscitation and he patient was dead.

DISCUSSION

PDE 5 inhibitors were developed as cardiovascular drugs and were incidentally found to enhance erections. Sildenafil citrate, is widely used to treat male erectile dysfunction, is a PDE 5 inhibitor. Since the introduction of the first sildenafil citrate, in 1998, there has been concern about the effects of

these agents on the heart and its safety in patients with cardiovascular disease [1]. These concerns can be collected to three subjects: effects on blood pressure and heart rate, effects on cardiac electrophysiology, and the number of cardiovascular adverse events.

Sildenafil citrate is mild vasodilators and generally constitutes slight few symptoms. Cardiac electrophysiology effects are especially manifested by changes in the QT interval. But Sildenafil is not dangerously associated with QTc prolongation. Cardiovascular adverse events caused by Sildenafil citrate are not signal for mortality and cannot be convincingly cited in studies which have conducted until now [1, 2]. An experimental study by Swissa et al [5] founded that Sildenafil-nitric oxide donor combination promotes the VT in the swine right ventricle. They concluded that Sildenafil citrate singly did not alter VT/VF vulnerability. In present study, there was no usage of nitric oxide donors in medical history of patient.

In the literature search, a case which occur VT following Viagra usage was reported but the death was not occurred and contrary to our case, the patient was discharged alive [6].

According to a report of the US Food and Drug Administration, of the 130 confirmed deaths among men who received sildenafil citrate, 77 had cardiovascular events, including 41 with myocardial infarction and 27 with cardiac arrest [6]. Cause of death was unknown in 48 and non-cardiac in 5 men and it has not been reported mortality due to VT in humans yet. To our knowledge, this case is a first case of a human resulting in death due to ventricular tachycardia (VT) following the use of Sildenafil singly. In conclusion, Sildenafil citrate ingestion might increase the incidence of VT and may be mortal.

CONFLICT OF INTEREST

No conflict of interest was declared by the authors.

FUNDING DISCLOSURE

The authors declared that this study has received no financial support.

This paper was presented as poster at 1st International Critical Care and Emergency Medicine Congress.

REFERENCE

1. Carson CC 3rd. (2005). Cardiac safety in clinical trials of phosphodiesterase 5 inhibitors. *Am J Cardiol.* 96(12B), 37M-41M.
2. Morganroth J, Ilson BE, Shaddinger BC, Dabiri GA, et al. (2004). Evaluation of vardenafil and sildenafil on cardiac repolarization. *Am J Cardiol.* (11), 1378-1383, A6.
3. Muñiz AE and Holstege CP. (2000). Acute myocardial infarction associated with Sildenafil (Viagra) ingestion. *Am J Emerg Med.* 18(3), 353-355.
4. Ekinozu I, Aslantas Y, Tibilli H, Turker Y, et al. (2013). The relationship between acute coronary syndrome and sildenafil. *Am J Emerg Med.* 31(9), 1424. e1-3.
5. Swissa M, Ohara T, Lee MH, Kaul S, et al. (2002). Sildenafil nitric oxide donor combination promotes ventricular tachyarrhythmias in the swine right ventricle. *Am J Physiol Heart Circ Physiol.* 282(5), H1787-1792.
6. Rasmussen JG, Toft E and Frøbert O. (2007). Ventricular tachycardia after administration of sildenafil citrate: A case report. *J Med Case Rep.* 1, 65.